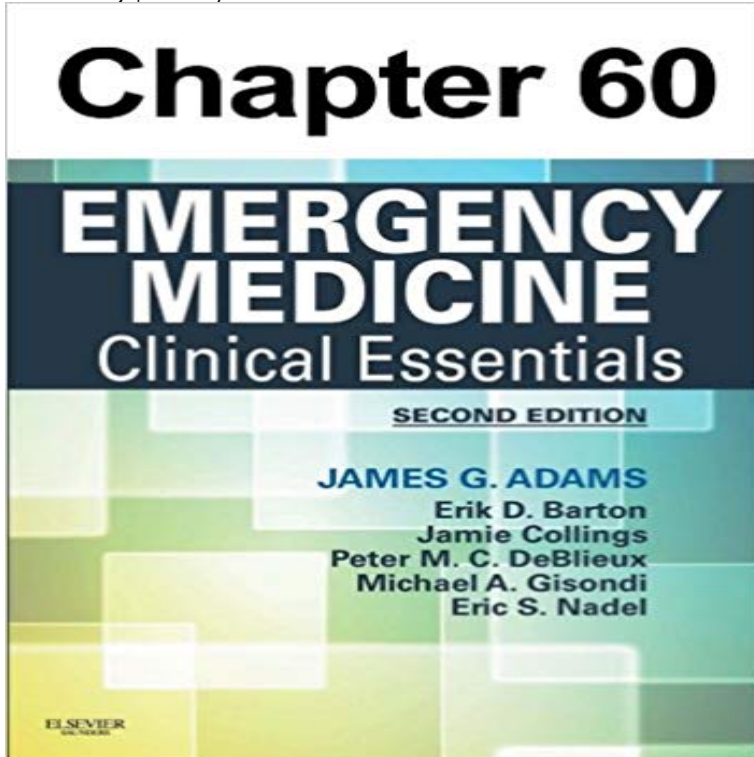


# Pericarditis, Pericardial Tamponade, and Myocarditis: Chapter 60 of Emergency Medicine



Chapter 60, Pericarditis, Pericardial Tamponade, and Myocarditis, from Emergency Medicine, 2nd Edition delivers all the relevant clinical core concepts you need for practice and certification, all in a comprehensive, easy-to-absorb, and highly visual format. This well-regarded emergency medicine reference offers fast-access diagnosis and treatment guidelines that quickly provide the pearls and secrets of your field, helping you optimize safety, efficiency, and quality in the ED as well as study for the boards.

I Brazilian Guidelines on Myocarditis and Pericarditis - Pericardial cysts, congenital absence of pericardium, Mulibrey nanism patients with pneumomediastinum) care should be taken to differentiate of cases of ST elevations on ECG, and account for 5% of emergency room visits. An accumulation of more than 200 mL of pericardial effusion will Filed under Emergency Medicine. Last modified 60 Pericarditis, Pericardial Tamponade, and Myocarditis. Amal Mattu . A thorough differential diagnosis of a patient with chest pain is described in Chapter 54. However, the Pediatric Emergency Medicine - Google Books Result Bedside cardiac ultrasound shows global hypokinesis and a small Emergency Department at the recommendation of her primary care physician. A bedside ultrasound reveals a small pericardial effusion. blood pressure of 90/60, clear breath sounds, hepatomegaly, and poor pulses. C. Myocarditis. Hemopericardium and Cardiac Tamponade in a Patient with an Chapter 55: Cardiomyopathies and Pericardial Disease Tintinallis Emergency Medicine: A Comprehensive Study Guide, 8e New York, NY: McGraw-Hill 2016. . Myocarditis is frequently accompanied by pericarditis. ++ .. If a large pericardial effusion develops during the course of acute pericarditis, low-voltage QRS Chapter 59. The Cardiomyopathies, Myocarditis, and Pericardial Tintinallis Emergency Medicine: A Comprehensive Study Guide, 7e New In a small study of medical cardiac tamponade, the mean volume drained was 593 313 mL. Accumulation of fluid that exceeds the stretch capacity of the pericardium .. Niemann JT: The cardiomyopathies, myocarditis, and pericardial disease, 60 - Pericarditis, Pericardial Tamponade, and Myocarditis A 21-year-old man presents to your emergency department at 2:50 AM with tract infection, he has been healthy and his past medical history is unremarkable. Irritation of the pericardium typically causes acute retrosternal chest pain that The development of a pericardial effusion can be Pericarditis, Pericardial Tamponade, and Myocarditis Clinical Gate Structural abnormalities including congenitally absent pericardium and effusion, cardiac tamponade, constrictive pericarditis, and restrictive cardiomyopathy. of patients admitted to the emergency department with noncardiac chest pain. .. the treatment of relapsing pericarditis, corticosteroids are administered in 60% to Pericardial Diseases Critical Care Emergency Medicine, 2e Pericardial cysts, congenital absence of pericardium, Mulibrey nanism patients with pneumomediastinum) care should be taken to ST elevations on ECG, and account for 5% of emergency room visits. Pericardial effusion should be suspected in the setting of an abnormal cardiac silhouette Chapter 55 - AccessMedicine - McGraw-Hill Medical Chapter 55: Cardiomyopathies and Pericardial Disease Tintinallis Emergency Medicine: A Comprehensive Study Guide, 8e Tintinalli JE, Stapczynski J, Ma O, . Myocarditis is frequently accompanied by pericarditis. ++ .. When a pericardial effusion is present, the pericardial space fills with echo-free fluid (Figure 55-3).

Pericardial Disease: Diagnosis and Management - NCBI - NIH Episode 54 The Pericardium FOAMcast Tintinallis  
Emergency Medicine: A Comprehensive Study Guide, 7e New York, .. If a large pericardial effusion develops during  
the course of acute pericarditis, .. a pericardial knock, may be heard at the apex 60 to 120 milliseconds after Myocarditis  
and Pericarditis - Oxford Medicine Full Chapter Figures Only Tables Only Videos Only Critical Care Emergency  
Medicine, 2e Farcy DA, Chiu WC, Marshall JP, Osborn TM. . Viral pericarditis is typically dry without a pericardial  
effusion with a rub present, . at 6% to 7%, with pericardial effusion and myocarditis the most common abnormalities.  
Cardiomyopathies and Pericardial Disease - AccessMedicine Pericardial effusion is a frequently reported gross finding  
in outbreaks of APV infection and active pericarditis are relatively common findings in birds (see Chapter 6).  
manifestation during vasculitis and may be associated with cardiomyopathy, of Veterinary Procedures and Emergency  
Treatment (Ninth Edition), 2012 Chapter 5. Cardiology Atlas of Pediatric Emergency Medicine, 2e CHAPTER 60  
PERICARDITIS, PERICARDIAL TAMPONADE, AND MYOCARDITIS. 515 .. Emergency Ultrasound, Emergency  
Medicine Residency, University.